

Marco Tallarico, Erta Khanari, Milena Pisano, Fulvio Gatti, Silvio Mario Meloni

Molar replacement with 7 mm-wide diameter implants: to place the implant immediately or to wait 4 months after socket preservation? 1 year after loading results from a randomised controlled trial

Key words delayed implants, dental implants, post-extractive implants, socket preservation, wide-diameter implants



Marco Tallarico DDS, MSc
Adjunct Professor, Aldent University Tirana, Albania, Private Practice, Roma, Italy

Erta Khanari DDS
Private Practice, Tirana, Albania

Milena Pisano DDS
Private Practice, Arzachena, Italy

Fulvio Gatti, DDS, MSc
Private Practice, Milan, Italy

Silvio Mario Meloni DDS, PhD, MSc
Adjunct Professor, University of Sassari, Italy, Private Practice, Arzachena, Italy

Correspondence to:
Marco Tallarico
Via di Val Tellina
116, 00151 Roma
Tel 0039 066630646
me@studiomarcotallarico.it

Purpose: To test the hypothesis that there is no difference in clinical, radiographic and aesthetic outcomes positioning single post-extractive 7 mm-diameter implants or waiting 4 months after molar extraction and socket preservation procedure.

Material and Methods: Patients requiring one implant-supported single restoration to replace a failing tooth in the molar region of both maxilla and mandible were selected. Patients were randomised according to a parallel group design into two arms: implant installation in fresh extraction sockets grafted with cortico-cancellous heterologous bone and porcine derma (group A) or delayed implant installation 4 months after tooth extraction and socket preservation using the same materials (group B). Implants were submerged for 4 months. The primary outcome measures were the success rates of the implants and prostheses and the occurrence of any surgical and prosthetic complications during the entire follow-up. Secondary outcome measures were: peri-implant marginal bone level (MBL) changes, resonance frequency analysis (ISQ) and pink esthetic score (PES) values at implant placement (baseline) up to 1 year after loading.

Results: Twelve patients were randomised to group A and 12 to group B. No patient dropped out within 1 year after loading. No implant and prosthesis failed and no complications occurred during the entire follow-up. One year after loading, statistically significant higher mean MBL loss was experienced in group A ($0.63 \text{ mm} \pm 0.31 \text{ mm}$) compared to group B ($0.23 \text{ mm} \pm 0.06 \text{ mm}$); difference 0.41 mm (95% CI $0.17\text{--}0.53$; $P = 0.001$). Six months after implant placement, mean ISQ value was 78.8 ± 2.8 for group A and 79.9 ± 3.6 for group B, showing no statistically significant difference between groups (difference 1.1 ; 95% CI: 0.04 to 2.96 ; $P = 0.422$). One year after loading, mean PES was 10.6 ± 1.8 [range: 8 to 13] in group A and 12.2 ± 1.2 [range: 11 to 14] in group B. The difference was statistically significant (1.6 ± 2.7 ; 95% CI $-0.55\text{--}2.55$; $P = 0.019$) with better results for group B.

Conclusions: Within the limitations of this study, both procedures achieved successful results over the 1-year follow-up period, but waiting 4 months after tooth extraction and socket preservation procedure was associated with less marginal bone loss and a better aesthetic outcome.

Conflict-of-interest statement: Dr Marco Tallarico is Research Project Manager of Osstem AIC Italy. However no company supported this study and all authors declare no conflicts of interest.



■ Introduction

Following tooth extraction the alveolar ridge undergoes a remodelling process that can influence implant therapy in the edentulous area¹. A recent systematic review concluded that after 6 months of healing, the vertical resorption of the alveolar bone ranged from 11 to 22%, whereas the horizontal resorption of the alveolar bone ranged from 29 to 63%². Previous tooth condition, as well as damage to the bone tissue during tooth removal, may result in additional bone loss³. To prevent this condition, socket preservation techniques^{4,5} or immediate placement of dental implants into fresh extraction sockets have been proposed⁶⁻⁹. Most preservation techniques were based on a careful tooth extraction, filling of the alveolar socket with different grafting materials and seal procedures, and undisturbed healing. Despite that, in a recent systematic review Atieh et al¹⁰ concluded there is limited evidence that alveolar ridge preservation techniques may minimise the overall changes in residual ridge height and there is no convincing evidence of any clinically significant difference between different grafting materials and barriers used.

It has been hypothesised that immediate implant placement in fresh extraction sockets may limit the extent of bone remodelling, avoiding the need for further bone augmentation procedures, as horizontal peri-implant defects less than 2 mm are usually spontaneously filled during bone healing¹¹.

Nevertheless, the literature concerning implants inserted into fresh extraction sockets is controversial. Some studies suggest that implants cannot preserve the alveolar bone and that immediate implant insertion in dental sockets is an unpredictable treatment, with many aesthetic problems due to vestibular cortex resorption^{12,13}. Conversely, other authors reported a high implant success rate when dental implants were inserted immediately after teeth extraction^{14,15}. Furthermore, in molar extraction sockets, immediate implant installation could be challenging due to anatomical limitations, such as the inferior alveolar nerve, as well as the maxillary sinus. Wide-diameter implants of different lengths were introduced to overcome the limitations of reduced bone height and to enhance the bone-to-implant contact (BIC) area, increasing the surface area for osseointegration¹⁶.

An interim 6-month post-loading report from this study showed statistically significant difference in marginal bone loss between groups from both two- and three-dimensional images¹⁷. However, implant stability quotient (ISQ) and pink aesthetic score (PES) were similar. This research presents the 1-year after loading results of this study.

The aim of the present randomised controlled trial of parallel group design was to evaluate patients with mandibular and maxillary hopeless molars, requiring an implant-supported single crown restoration. The test hypothesis was there is no difference in clinical, radiographic and aesthetic outcomes positioning single post-extractive 7 mm-wide diameter implants or waiting 4 months to place the implant, after molar extraction and socket preservation procedure. This null hypothesis was tested against the alternative hypothesis of differences between them. This trial has been reported in accordance with the guidelines provided by the CONSORT statement for the evaluation of randomised controlled trials (<http://www.consort-statement.org>).

■ Materials and Methods

The randomised controlled trial (RCT) was conducted at a private practice in Rome between June and December 2014. The last follow-up was in September 2016. Any subject requiring one implant-supported single restoration to replace a failing tooth in the molar region of both jaws, with less than 5 mm between the root apex and the inferior alveolar nerve or maxillary sinus, measured on the CBCT scan, being at least 18 years old and able to sign an informed consent, was considered eligible for this study and consecutively enrolled. Fresh extraction sockets had to have intact buccal walls. The same clinician (MT) performed both surgical and prosthetic procedures.

The exclusion criteria were:

- General contraindications to oral surgery (such as stroke, recent cardiac infarction, a severe bleeding disorder, uncontrolled diabetes or cancer).
- Heavy smokers (≥ 11 cigarettes/day).
- Addiction to alcohol or drugs.
- Acute and chronic infections in the site intended for implant placement.

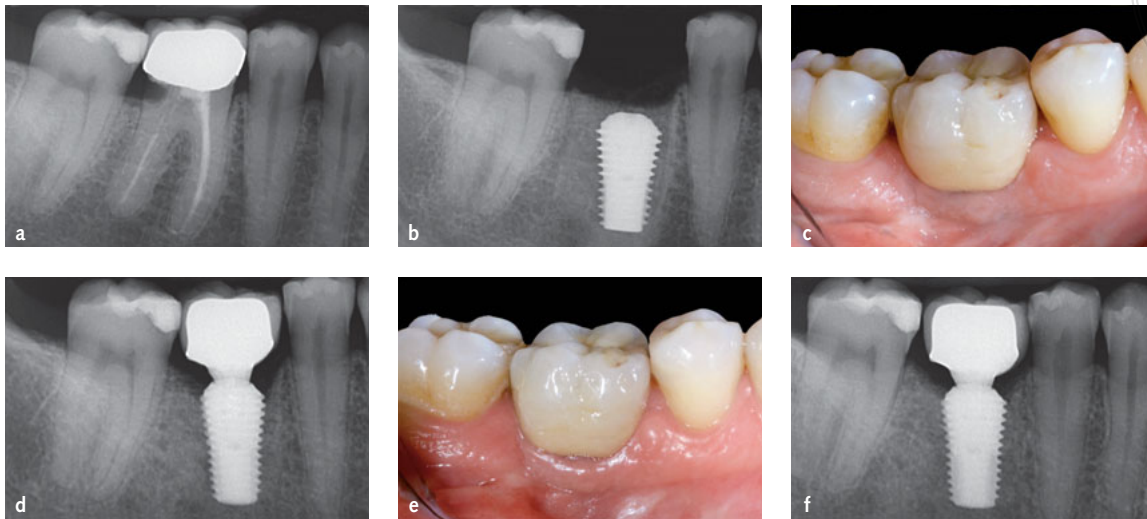


Fig 1a to f Treatment sequence of one of the patients randomly allocated to immediate post-extractive implant (group A): a) pre-operative radiograph of the lower molar in position 46; b) immediate implant installation; c) final crown delivery; d) peri-apical x-ray at crown delivery; e) 1 year after loading; f) peri-apical x-ray 1 year after loading.

- Poor oral hygiene, defined as full mouth bleeding and full mouth plaque index higher than 25%.
- Pregnancy or nursing.
- Psychiatric therapy.
- Patients treated or under treatment with intravenous amino-bisphosphonates.
- Previous radiotherapy of the oral and maxillofacial region within the past 5 years;
- Absence of teeth in the opposing jaw;
- Severe clenching or bruxism;
- Patients unable to commit to the scheduled follow-up.

Each patient considered for the present study received only one implant. The selected site had to have both adjacent teeth/implants. A written informed consent for surgical and prosthetic procedures and the use of the clinical and radiological data was obtained for each patient.

■ Tooth extraction

Patients received professional oral hygiene treatment prior to surgery and were instructed to use chlorhexidine mouthwash 0.2% (Corsodyl, GlaxoSmithKline, Verona, Italy) for 1 min, twice a day, starting 3 days prior to implant placement and thereafter for 1 week.

Antibiotic therapy consisting of 2 g of amoxicillin and clavulanic acid or 600 mg clindamycin, if

allergic to penicillin, was given 1 h prior to surgery. After that 1 g of amoxicillin (or 300 mg of clindamycin) was administered every 12 h for 5 days after tooth extraction. All patients were treated under local anaesthesia using articain hydrochloride with adrenaline 1:100000 (Orabloc, Pierrel, Milan, Italy). Extractions were performed atraumatically, with the aid of a periosteal elevator and atraumatic elevators (PT1 and EPTSMS, Hu-Friedy, Milan, Italy). Multiple-rooted teeth were sectioned at the furcation and the roots were individually extracted. Afterwards, the residual extraction socket was washed with physiological solution and debrided thoroughly from granulation tissue and residual periodontal ligament fibres with a curette (CL866, Hu-Friedy). After assessing the integrity of the socket walls with a periodontal probe (PCPUNC156, Hu-Friedy), a dental assistant opened the sequentially numbered sealed envelope corresponding to the patient recruitment number to know whether to place the implant (group A), (Fig 1a to f) or to preserve the socket (group B), (Fig 2a to 2f).

■ Implant placement

The same implants were used (Ultra-Wide, Osstem, Seoul, Korea). For group A, the initial osteotomy was made into the interradicular bone using the 2 mm sidecut pilot drill (Osstem, Korea). In case of thin interradicular septa, a high-speed round diamond

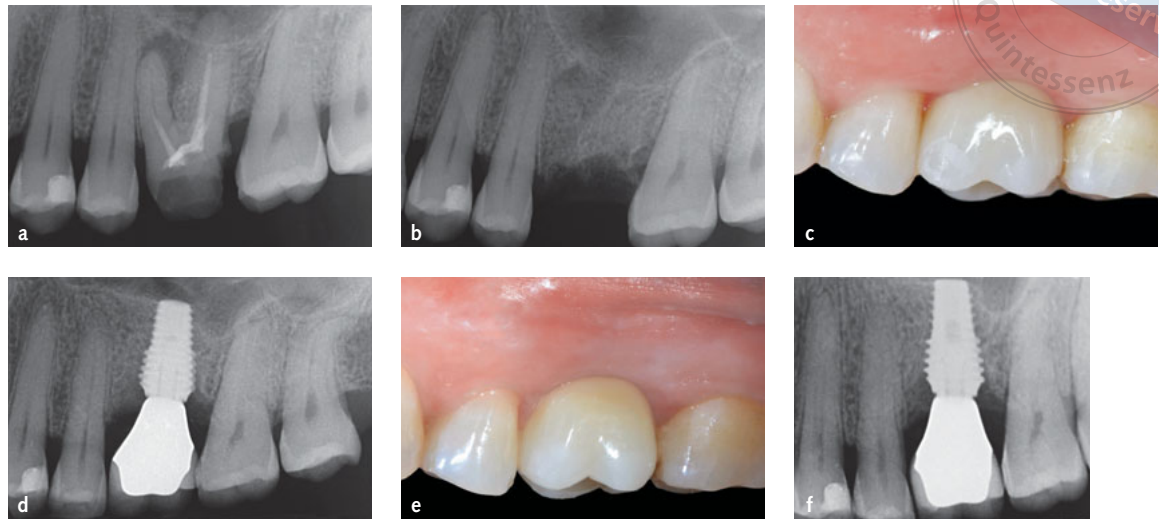


Fig 2a to f Treatment sequence of one of the patients randomly allocated to delayed implant placement (group B): a) pre-operative picture upper molar in position 26; b) 4 months after socket preservation; c) final crown delivery; d) peri-apical x-ray at final crown delivery; e) final crown 1 year after loading; f) final crown 1 year after loading

bur was used under copious irrigation with sterile saline to mark the central part of the interradicular bone. The preparation of the osteotomy continued with the use of the implant-tapered drills (Tapered and Ultra-Kit, Osstem, Korea) in the centre of the socket and in relation to the desired axis of the planned rehabilitation. Afterwards the 7-mm diameter implant was immediately placed, at crest level or slightly below, engaging both the prepared interradicular bone and the socket walls. The surgical motor (iChiropro, Bien-Air Medical Technologies, Bienne, Switzerland) was set at a speed of 25 rpm with a 45 Ncm torque. The primary stability was also evaluated using the Osstell Mentor device (Osstell, AB, Göteborg, Sweden). Thereafter, the residual alveolar socket around the implant was grafted with cortico-cancellous heterologous porcine bone, with graft particle size between 250 and 1000 μm (GEN-OS OsteoBiol, Tecnos, Coazze, Italy) and the socket was covered by suturing (Vicryl V271, Ethicon, West Somerville, NJ, USA), a resorbable porcine derma membrane (Derma, OsteoBiol). In group B, socket preservation and seal closure procedures were performed with the same procedure described for group A, but the ultra-wide 7 mm-diameter implant was placed conventionally 4 months later according to the drilling protocol and clinical guideline suggested by the manufacturer.


In both groups, 500 mg paracetamol plus 30 mg codeine was prescribed as needed, and patients were

carefully instructed not to take them in the absence of pain. A soft diet was recommended for two weeks after surgical procedures. All patients were recalled and checked 1 week and 1 month after tooth extraction/implant placement.

In both groups, 4 months after implant placement, a second stage surgery was performed making the incision slightly palatal/lingual to have more keratinised tissues on the buccal side. A 5 mm-diameter healing abutment of different lengths was placed, but no temporary restoration was delivered. The blind assessor manually tested the implant for stability, tightening the abutment with a 20 Ncm torque. Two months after second-stage surgery a lithium disilicate single crown, bonded chairside on a CAD/CAM (Computer-Aided-Design/Computer-Aided-Manufacturing) zirconia abutment, was screw-retained. The occlusion was adjusted avoiding any eccentric contacts. Periapical radiographs and clinical pictures were taken. Follow-up visits were scheduled every 3 months up to 1 year after implant loading.

■ Outcome measures

- Implant failure was defined as implant mobility and/or any infection dictating implant removal, or implant fracture, or any other mechanical complication rendering the implant useless. The stability of each individual implant was measured



manually by tightening the abutment screw at the delivery of definitive crowns or by assessing the stability of the implant-supported crown using the handle of two metallic instruments at 6 and 12-month follow-ups.

- A prosthesis was considered a failure if it needed to be replaced.
- Any biologic (e.g. pain, swelling, mobility, suppuration) and/or technical complications (e.g. abutment and/or veneering material fracture, screw loosening and/or fracture) were recorded during follow-ups by the operator (MT), who performed all the surgical and prosthetic procedures.
- Mesial and distal bone level changes were measured as the distance from the mesial and distal margin of the implant neck (inserted slightly below the buccal bone level) to the most coronal point where the bone appeared to be in contact with the implant. For each implant, mean values of mesial and distal measurements were averaged. It was evaluated on periapical digital radiographs taken with the paralleling technique using a film-holder (Rinn XCP, Dentsply, Elgin, IL, USA) taken at implant placement (baseline), at initial loading (definitive prosthesis delivery), and at 6 and 12 months after loading. All readable radiographs were displayed in an image analysis program (DFW2.8 for Windows, Soredex, Tuusula, Finland), calibrated for every single image using the known distance of two consecutive implant threads pitch. In the case of a not properly readable radiograph, the radiograph was made again. A blinded dentist not previously involved in the study (EX) measured all the radiographs
- The aesthetic evaluation was performed according to the pink aesthetic score (PES) on the vestibular and occlusal pictures taken including at least one adjacent tooth per side¹⁸. The values were assessed at 6- and 12-month after loading follow-up examinations. Seven variables (mesial papilla, distal papilla, soft-tissue level, soft-tissue contour, alveolar process deficiency, soft-tissue colour and texture) were assessed with a 2-1-0 score (2 being best and 0 being poorest) by the same blinded dentist (EX).
- Implant stability quotient (ISQ) was recorded by means of resonance frequency analysis by the same clinician that performed all the surgical and

prosthetic procedures. The values were assessed at implant placement (baseline) and immediately before prosthesis delivery (six months after implant placement), by using the Osstell Mentor device (Osstell, Sweden). Two measurements were taken for each implant: one buccopalatal from the buccal side and one mesiodistal from the mesial side and both measurements were averaged. The result was displayed by the device in ISQ units, with range from 1 to 100¹⁹.

■ Statistical analysis

A priori sample size was calculated for the radiographic peri-implant marginal bone level by means of G* Power 3.1.7 software for Mac OS X (version 10.9.2; University of Düsseldorf, Düsseldorf, Germany) given effect size $d = 0.7143$, error probability $\alpha = 0.05$, and power = 0.70 (1- β error probability), resulting in a sample size of 26 patients for each group. Effect size was expressed as Cohen's d and it was determined using previously reported data on similar topic published by Atieh et al⁴. That showed a higher bone gain of 0.41 ± 0.57 mm for the immediately placed implants, compared with 0.04 ± 0.46 mm for the delayed placed implants ($P = 0.14$).

A pre-generated random list, consisting of a randomised sequence of consecutive numbers matching the two different procedures within group A or group B, was created using Random number generator pro 1.91 for Windows (Segobit Software, Redmond, Washington USA). Opaque envelopes containing the randomisation codes were sequentially numbered and sealed. According to a pre-generated list, an independent clinician, not previously involved in the trial, prepared all the envelopes. Data were collected on spreadsheets (Excel software, Microsoft Corporation, Redmond, Washington, USA). All data analysis was carried out according to a pre-established analysis plan by a biostatistician with expertise in dentistry without knowing group allocation. The patient was the statistical unit of the analyses. A comparison of the baseline characteristics between groups was presented. Differences in the proportion for dichotomous outcomes (crown/implant failures and complications) were compared between the groups using Fisher's exact probability

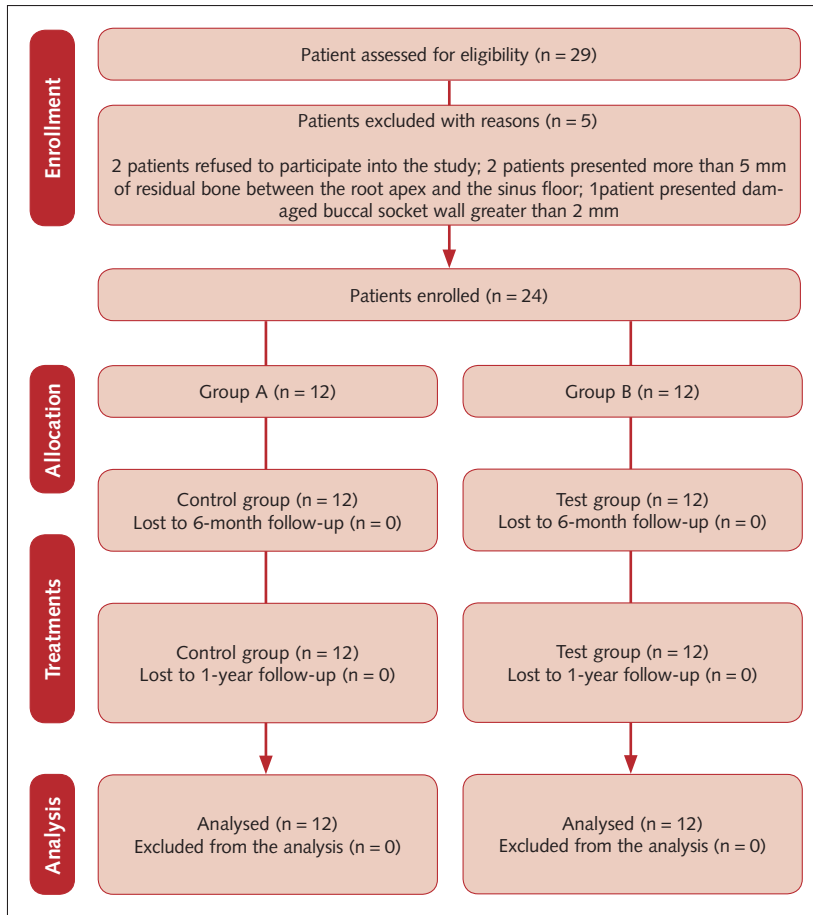


Fig 3 CONSORT flow diagram.

test. Differences among the groups for continuous outcomes (mean marginal bone level changes, ISQ and PES scores) were compared using analysis of variance (ANOVA). Differences relating to the mean marginal bone levels between groups were compared by *t* test. A within-group comparison was performed, with a *t* test for paired data. The Student *t* test was used to evaluate differences in peri-implant marginal bone level changes between the two treatment groups. All statistical tests were two-tailed with a significant level of 0.05. Statistical analysis was performed using SPSS for Mac OS X version 22.0 (SPSS, Chicago, IL, USA).

■ Results

A flow diagram of the screening and enrolment process is shown in Figure 3. In total, 29 patients were screened between June and December 2014, but five were not enrolled because two patients refused


to participate in the study; two maxillary patients presented with more than 5 mm of residual bone between the root apex and the sinus floor; one patient presented a damaged buccal socket wall greater than 2 mm, without loss of soft tissue, after tooth extraction. Twenty-four patients (8 male, 16 female), with a mean age of 53.9 years (range, 37 to 67) were considered eligible for the study and consecutively treated (12 patients group A, 12 patients group B). A total of 24 procedures were performed and 24 implants (four 8.5 mm long, 18 with 10 mm long and two 11.5 mm long) placed. One patient became pregnant and did not undergo the 1-year radiograph. No deviation from the protocol occurred. All the data collected were included in the statistical analysis. There were no apparent baseline imbalances between the two groups, apart for the presence of longer implants in group B. The main patient and implant characteristics between groups are reported in Table 1.

At the 1-year post loading follow-up examination, no implants and prosthesis failed and no biological or mechanical complications occurred during the entire follow-up period.

At definitive prosthesis delivery, mean marginal bone loss was $0.41 \text{ mm} \pm 0.38 \text{ mm}$ (95% CI 0.03–0.47) in group A and $0.11 \text{ mm} \pm 0.09 \text{ mm}$ (95% CI 0.05–0.15) in group B. The difference was statistically significant (0.30 mm; 95% CI 0.00–0.40; $P = 0.02$). One year after loading, mean marginal bone loss was $0.63 \text{ mm} \pm 0.31 \text{ mm}$ (95% CI 0.42–0.78) in group A and $0.23 \text{ mm} \pm 0.06 \text{ mm}$ (95% CI 0.17–0.23) in group B. The difference was statistically significant (0.41 mm; 95% CI 0.17–0.53; $P = 0.001$). From implant loading to 1-year post-loading, mean marginal bone loss was $0.23 \text{ mm} \pm 0.20 \text{ mm}$ (95% CI 0.11–0.34) in group A and $0.12 \text{ mm} \pm 0.23$ (95% CI -0.03–0.23) in group B. The difference was not statistically significant (0.11 mm; 95% CI 0.05–0.15; $P = 0.237$). All data is reported in Table 2.

Six months after implant placement, mean ISQ value was 78.8 ± 2.8 for group A and 79.9 ± 3.6 for group B, showing no statistically significant differences between groups (difference 1.1; 95% CI: 0.04 to 2.96; $P = 0.422$).

Six months after loading PES was 10.7 ± 1.5 [range: 8–13] in group A and 11.7 ± 1.2 [range:

**Table 1** Main patient and implant characteristics.

	Group A (n = 12) Immediate post-extractive implants	Group B (n = 12) Delayed implants
Number of female patients (n = 16)	7 (58.3%)	9 (75.0%)
Number of male patients (n = 8)	5 (41.7%)	3 (25.0%)
Age at insertion (range)	51.6 (37-67)	56.2 (42-67)
Total number of smokers (<10 cigarettes per day)	0 (0%)	0 (0%)
Total number of mandibular implants	6 (50%)	6 (50%)
8.5 mm long implants	3 (25%)	1 (8.3%)
10 mm long implants	9 (75%)	9 (75%)
11.5 mm long implants	0 (0%)	2 (16.7%)
Implants in first molar position	10 (83.3%)	11 (91.7%)
Implants in second molar position	2 (16.7%)	1 (8.3%)

Table 2 Outcomes comparison between groups at 1 year after loading.

	Group A (n = 12) Immediate post-extractive implants	Group B (n = 12) Delayed implants	Difference	P value
Peri-implant marginal bone loss, mm \pm SD (95% CI)	0.63 \pm 0.31 (0.42–0.78)*	0.23 \pm 0.06 (0.17–0.23)	0.41 (0.17–0.53)	0.001°
Pink aesthetic score	10.6 \pm 1.8 (9.99–12.01)	12.2 \pm 1.2 (11.32–12.68)	1.6 (-0.55–2.55)	0.019°

*One patient became pregnant and has not undergone the 1-year radiograph.

°Statistically significant difference.

10–13] in group B, with no significant difference between groups (difference 1.0; 95% CI -0.23–2.23; $P = 0.081$). One year after loading, mean PES slightly improved in the control A, but not in group B: 10.6 \pm 1.8 [range: 8 to 13] in group A and 12.2 \pm 1.2 [range: 11 to 14] in group B. The difference was statistically significant (1.6; 95% CI -0.55–2.55; $P = 0.019$; (Table 2). A sub-analysis of the pink aesthetic score variables confirmed that the level of soft tissue margin and the soft-tissue colour showed statistically lower values in group A compared to group B (Table 3).


■ Discussion

This RCT aimed to investigate which procedure would be preferable, after extracting a hopeless molar in both jaws – immediate post-extractive 7 mm-diameter implants in combination with socket preservation procedures or socket preservation procedure alone, with delayed implant placement. This RCT revealed statistically significant differences both

in MBL and PES values between the two investigated approaches, with better values for socket preservation procedure and delayed implant placement. Therefore, the null hypothesis of the present study was rejected in favour of the alternative hypothesis of difference.

The main limitations of this study are the limited power of the analysis due to a limited number of participants, and the short follow-up period. Originally the study was designed as multicentre, but only one centre started the study. Unfortunately, the authors were unable to comply with the original planned sample size. These results confirm our preliminary report 6 months after loading in terms of survival rate and complications¹⁷. Moreover, these data are in accordance with other previously published studies on wide-diameter implants achieving high success rates under both conventional and immediate conditions^{20–22}.

The 1-year post-loading results of this study seem to confirm a trend of different clinical outcomes in favour of the delayed approach. The major clinical conclusion of this RCT was that single post-extractive

**Table 3** Pink aesthetic score values between groups.

	Variables	Mesial papilla	Distal papilla	Soft tissue level	Soft tissue contour	Alveolar process deficiencies	Soft tissue Colour	Soft tissue texture
Immediate post-extractive implant (Group A)	Patient 1	1	1	0	2	2	0	2
	Patient 2	1	1	0	2	2	1	2
	Patient 3	1	1	2	2	2	1	2
	Patient 4	2	2	2	2	1	2	2
	Patient 5	1	1	2	2	2	2	2
	Patient 6	2	2	0	2	2	1	2
	Patient 7	1	1	0	2	1	1	1
	Patient 8	1	1	2	2	2	1	2
	Patient 9	2	1	2	2	1	2	2
	Patient 10	1	2	0	2	2	1	2
	Patient 11	2	1	1	2	2	2	2
	Patient 12	1	2	1	2	2	1	2
Mean±SD		1.33±0.49	1.42±0.51	1.0±0.95	1.92±0.29	1.75±0.45	1.25±0.62	1.92±0.29
Delayed implant placement (Group B)	Patient 1	2	2	2	2	2	2	2
	Patient 2	2	2	1	2	2	2	2
	Patient 3	1	1	2	2	2	1	2
	Patient 4	2	2	1	2	1	2	1
	Patient 5	2	2	2	1	2	1	2
	Patient 6	1	2	1	2	2	2	1
	Patient 7	2	2	2	2	2	2	2
	Patient 8	2	1	2	2	1	2	2
	Patient 9	1	2	1	1	2	2	2
	Patient 10	1	1	2	2	2	2	1
	Patient 11	2	2	2	2	2	1	2
	Patient 12	2	1	2	2	2	2	2
Mean±SD		1.67±0.49	1.67±0.49	1.67±0.49	1.83±0.39	1.83±0.39	1.75±0.45	1.75±0.45
P value		0.111	0.237	0.047°	0.558	0.663	0.036°	0.296


°Statistically significant difference.

7 mm-diameter implants may be considered with caution as treatment option in the short-term to rehabilitate a hopeless molar when patients desire to shorten the overall treatment time and to reduce the number of surgical procedures. Data obtained from this trial confirms that from previous study. In fact wide implants inserted in post-extraction sockets undergo more bone remodelling also 1 year after loading that is indicative of a possible soft tissue instability, and it should be investigated with longer follow-ups.

Such difference could be referred primarily to the reduction of the socket preservation effect placing a wide diameter implant at crestal level. In fact, as

described in our 6-month after loading preliminary report¹⁷, statistical differences between groups were reported not only for peri-implant marginal bone loss, but also for the horizontal bone loss, measured with standardised CBCT scan at levels localised 1, 2, and 3 mm below the most coronal aspect of the bone crest. Particularly, this study showed significantly higher vestibular bone resorption when implants were placed immediately¹⁷.

In the present study, although no immediate loading protocol was planned, the 7 mm-diameter implants used achieved high implant stability for both post-extractive and healed sites, with no statistically significant differences in ISQ values between them at



each follow-up. These results are in accordance with other similar studies, confirming that a high primary implant stability is positively associated with a successful immediately loaded implant integration and long-term successful clinical outcomes²³⁻³².

In the preliminary 6-month report of this study, the soft tissue aesthetics were rated with a mean PES of 10.7 in group A and 11.7 in group B, with no significant difference between groups (difference 1.0; 95% CI -0.23–2.23; $P = 0.081$) 6 months after loading¹⁶. After 12 months of loading, PES values were 10.6 in group A and 12.2 in group B. The difference was statistically significant (1.6; 95% CI -0.55–2.55; $P = 0.019$). These changes are due to a PES slightly improving in the preservation group, but not in the immediate post-extractive group. These differences were significant for both the level of soft tissue margin and soft tissue colour, confirming that the delayed approach is associated with a better soft tissues response. Although no clinical soft tissue recession around the implant neck was recorded in either groups, soft tissue levels and soft tissue colour parameters were worse in the post-extractive group.

■ Conclusions

Within the limitations of this study, both procedures achieved successful results over a 1-year follow-up period, but waiting 4 months after tooth extraction and socket preservation procedure was associated with less marginal bone loss and better aesthetic outcome.

■ References

1. Van der Weijden F, Dell'Acqua F, Slot DE. Alveolar bone dimensional changes of post-extraction sockets in humans: a systematic review. *J Clin Periodontol* 2009;36:1048–1058.
2. Tan WL, Wong TLT, Wong MCM, Lang NP. A systematic review of post-extraction alveolar hard and soft tissue dimensional changes in humans. *Clin Oral Implants Res* 2012;23(Suppl 5):1–21.
3. Schropp L, Wenzel A, Kostopoulos L, Karring T. Bone healing and soft tissue contour changes following single-tooth extraction: a clinical and radiographic 12-month prospective study. *Int J Periodontics Restorative Dent* 2003;23:313–323.
4. Atieh MA, Alsabeeha NHM, Duncan WJ, de Silva RK, Cullinan MP, Schwass D, Payne AG. Immediate single implant restorations in mandibular molar extraction sockets: a controlled clinical trial. *Clin Oral Implants Res* 2012;24:484–496.
5. Meloni SM, Tallarico M, Lolli FM, Deledda A, Pisano M, Jovanovic SA. Postextraction socket preservation using epithelial connective tissue graft vs porcine collagen matrix. 1-year results of a randomised controlled trial. *Eur J Oral Implantol* 2015;8:39–48.
6. Esposito M, Grusovin MG, Polyzos IP, Felice P, Worthington HV. Timing of implant placement after tooth extraction: immediate, immediate-delayed or delayed implants? A Cochrane systematic review. *Eur J Oral Implantol* 2010;3:189–205.
7. Schropp L, Wenzel A, Stavropoulos A. Early, delayed, or late single implant placement: 10-year results from a randomized controlled clinical trial. *Clin Oral Implants Res* 2014;25:1359–1365.
8. Esposito M, Barausse C, Pistilli M, Jacotti M, Grandi G, Tucco L, Felice P. Immediate loading of post-extractive versus delayed placed single implants in the anterior maxilla: outcome of a pragmatic multicenter randomised controlled trial 1-year after loading. *Eur J Oral Implantol* 2015;8:347–358.
9. Felice P, Pistilli R, Barausse C, Trullenque-Eriksson A, Esposito M. Immediate non-occlusal loading of immediate post-extractive versus delayed placement of single implants in preserved sockets of the anterior maxilla: 1-year post-loading outcome of a randomised controlled trial. *Eur J Oral Implantol* 2015;8:361–372.
10. Atieh MA, Alsabeeha NHM, Payne AGT, Duncan W, Faggon CM, Esposito M. Interventions for replacing missing teeth: alveolar ridge preservation techniques for dental implant site development. *Cochrane Database of Systematic Reviews* 2015;5:CD010176.
11. Chen ST, Darby IB, Reynolds EC. A prospective clinical study of non-submerged immediate implants: clinical outcomes and esthetic results. *Clin Oral Implants Res* 2007;18:552–562.
12. Araujo MG, Sukekava F, Wennstrom JL, Lindhe J. Tissue modeling following implant placement in fresh extraction sockets. *Clin Oral Implants Res* 2006;17:615–624.
13. Araujo MG, Wennstrom JL, Lindhe J. Modeling of the buccal and lingual bone walls of fresh extraction sites following implant installation. *Clin Oral Implants Res* 2006;17:606–614.
14. Villa R, Rangert B. Immediate and early function of implants placed in extraction sockets of maxillary infected teeth: a pilot study. *J Prosthet Dent* 2007;97:S96–S108.
15. Villa R, Crespi R, Cappare P, Gherlone E. Immediate loading of a dental implant placed in fresh socket with acute dehiscence-type defect: a clinical case report. *J Periodontol* 2010;81:953–957.
16. Paolantonio M, Dolci M, Scarano A, d'Archivio D, di Placido G, Tumini V, Piattelli A. Immediate implantation in fresh extraction sockets. A controlled clinical and histological study in man. *J Periodontol* 2001;72:1560–1571.
17. Tallarico M, Khanari E, Pisano M, De Riu G, Tullio A, Meloni SM. Single post-extractive ultra-wide 7 mm-diameter implants versus implants placed in molar healed sites after socket preservation for molar replacement: 6-month post-loading results from a randomised controlled trial. *Eur J Oral Implantol*. 2016;9:263–275.
18. Furhauer R, Florescu D, Benesch T, Haas R, Mailath G, Watzek G. Evaluation of soft tissue around single-tooth implant crowns: the pink esthetic score. *Clin Oral Implants Res* 2005;16:639–644.
19. Tallarico M, Vaccarella A, Marzi GC, Alviani A, Campana V. A prospective case-control clinical trial comparing 1- and 2-stage Nobel Biocare TiUnite implants: resonance frequency analysis assessed by Osstell Mentor during integration. *Quintessenz Int*. 2011 Sep;42:635–44.
20. Bahat O, Handelsman M. Use of wide implants and double implants in the posterior jaw: A clinical report. *Int J Oral Maxillofac Implants* 1996;11:379–386.

21. Esposito M, Pistilli R, Barausse C, Felice P. Three-year results from a randomised controlled trial comparing prostheses supported by 5-mm long implants or by longer implants in augmented bone in posterior atrophic edentulous jaws. *Eur J Oral Implantol*. 2014;7:383–395.
22. Peñarocha-Diago M, Carrillo-García C, Boronat-Lopez A, García-Mira B. Comparative study of wide-diameter implants placed after dental extraction and implants positioned in mature bone for molar replacement. *Int J Oral Maxillofac Implants* 2008;23:497–501.
23. Kim YK, Kim JH, Yi YJ, Yun PY, Kim SG, Oh JS, Kim JS. A Retrospective Case Report Series of Clinical Outcomes with Moderately Rough, Wide-Diameter 8-mm Implants in the Posterior Maxilla. *Int J Periodontics Restorative Dent* 2013;33:e95–e100.
24. Vittorini Orgeas G, Clementini M, De Risi V, De Sanctis M. Surgical techniques for alveolar socket preservation: A systematic review. *Int J Oral Maxillofac Implants* 2013;28:1049–1061.
25. Pozzi A, Tallarico M, Moy PK. Immediate loading with a novel implant featured by variable-threaded geometry, internal conical connection and platform shifting: Three-year results from a prospective cohort study. *Eur J Oral Implantol* 2015;8:51–63.
26. Tallarico M, Vaccarella A, Marzi GC, Alviani A, Campana V. A prospective case-control clinical trial comparing 1- and 2-stage Nobel Biocare TiUnite implants: resonance frequency analysis assessed by Osstell Mentor during integration. *Quintessence Int* 2011;42:635–644.
27. Tallarico M, Meloni SM, Canullo L, Caneva M, Polizzi G. Five-year results of a randomized controlled trial comparing patients rehabilitated with Immediately loaded maxillary cross-arch fixed dental prosthesis supported by four or six implants placed using guided surgery. *Clin Implant Dent Relat Res* 2015 Oct 7. doi: 10.1111/cid.12380. [Epub ahead of print].
28. Meloni SM, De Riu G, Pisano M, Lolli FM, Deledda A, Campus G, Tullio A. Implant restoration of edentulous jaws with 3D software planning, guided surgery, immediate loading, and CAD-CAM full arch frameworks [epub ahead of print 29 July 2013]. *Int J Dent* 2013. doi:10.1155/2013/683423.
29. Meloni SM, De Riu G, Pisano M, Cattina G, Tullio A. Implant treatment software planning and guided flapless surgery with immediate provisional prosthesis delivery in the fully edentulous maxilla. A retrospective analysis of 15 consecutively treated patients. *Eur J Oral Implantol* 2010;3:245–251.
30. Ottoni JM, Oliveira ZF, Mansini R, Cabral A. Correlation between placement torque and survival of single-tooth implants. *Int J Oral Maxillofac Implants* 2005;20:769–776.
31. Cannizzaro G1, Leone M, Ferri V, Viola P, Gelpi F, Esposito M. Immediate loading of single implants inserted flapless with medium or high insertion torque: a 6-month follow-up of a split-mouth randomised controlled trial. *Eur J Oral Implantol*. 2012;5:333–42.
32. Muftu A1, Chapman RJ. Replacing posterior teeth with freestanding implants: four-year prosthodontic results of a prospective study. *J Am Dent Assoc* 1998;129:1097–1102.