

# Full Arch Restoration with Computer-Assisted Implant Surgery and Immediate Loading in Edentulous Ridges with Dental Fresh Extraction Sockets. One Year Results of 10 Consecutively Treated Patients

## Guided Implant Surgery and Extraction Sockets

Silvio Mario Meloni · Giacomo De Riu ·  
Milena Pisano · Antonio Tullio

Received: 14 May 2012 / Accepted: 15 July 2012 / Published online: 3 November 2012  
© Association of Oral and Maxillofacial Surgeons of India 2012

**Abstract** There is a growing need for patients to be rehabilitated with a fixed, implant-supported prosthesis immediately after surgery. The present study aims to describe the results of a modified prosthetic and surgical protocol of computer-assisted implant insertion and immediate loading in edentulous jaws with extraction sockets. Ten patients were consecutively treated with a modified computer assisted implant surgery protocol and screw-retained provisional metal-acrylic prosthesis prepared ahead of surgery and delivered immediately. Overall, 60 implants (Nobel Replace Tapered Groovy) were inserted, of which 22 were inserted in fresh extraction sockets. Definitive prosthesis was delivered after 6–12 months. Outcome measures were radiographic marginal bone-level changes, survival of implants, and patient satisfaction. The follow-up period was of at least 12 months. All the patients felt comfortable and none withdrew from the study. No implants were lost, resulting in a cumulative survival rate of 100 %. Radiological estimation showed a mean peri-implant marginal bone loss of  $1.4 \pm 0.3$  mm. No other complications, biological or mechanical, were recorded. In all cases, patients appeared to be very satisfied with the aesthetic and function. Within the limitations of this study, our data seem to validate this surgical and prosthetic protocol with valid functional and aesthetic results when applied in selected cases.

**Keywords** Immediate loading · Computer-aided implant surgery · Full-arch prosthesis · Fresh extraction socket

## Introduction

There are many reports on successful dental implants following computer-guided surgery using the All-on-Four and All-on-Six concepts (Nobel Guide, Nobel Biocare) [1–3]. The one-stage surgical procedure, combined with early and immediate implant function has been proven to be a valid approach in full-arch edentulous patients. Computer-aided implant surgery minimizes positioning error compared to manual or conventional-guided placement [4, 5] and makes it possible to fabricate a provisional restoration prior to surgery.

There is a growing need for patients to be rehabilitated with a fixed, implant-supported prosthesis immediately after surgery, not only to minimise patient discomfort but also to restore functionality and aesthetics quickly so that patients can return to their normal routine within a short period of time. Moreover, patients often request such prostheses to avoid wearing removable prostheses for a few months.

Consequently, many researchers have attempted to analyse implant insertion in fresh extraction sockets with immediate loading even in the chronically infected alveolar bone [6]. Others have developed new computer-assisted implant insertion protocols with the aim of inserting the implant into fresh extraction sockets and preserving alveolar bone volume [7].

The present study describes results after 1 year of a modified prosthetic and surgical protocol for computer-assisted implant insertion in edentulous jaws and extraction sockets for patients in need of a full cross-arch implant-supported prosthesis.

---

S. M. Meloni · G. De Riu · M. Pisano · A. Tullio  
Maxillofacial Surgery Unit, University Hospital of Sassari,  
Sassari, Italy

S. M. Meloni (✉)  
Cattedra e U.O. Chirurgia Maxillo-Facciale, Università degli  
Studi di Sassari, Viale San Pietro 43/B, 07100 Sassari, Italy  
e-mail: melonisilviomario@yahoo.it

## Methods

This study was designed as a prospective clinical trial. The study was conducted at the Oral and Maxillofacial Surgery Unit of the University Hospital of Sassari, Italy, and was approved by the local ethics board, following Helsinki Declaration guidelines. Ten patients in need of rehabilitation were consecutively treated with computer-assisted implant insertion (Nobelguide protocol, Nobel Biocare Gothenburg Sweden).

All procedures were carried out with adequate understanding and written consent of the subjects.

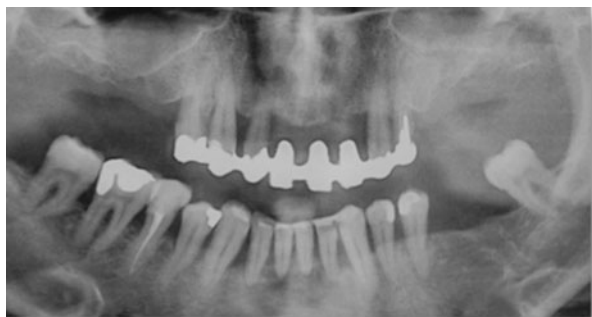All patients underwent the same procedure: computer-guided flapless implant insertion and implant immediate loading with a screw-retained provisional prosthesis.

One patient who was rehabilitated on the upper and lower jaw, was treated with this protocol only on the mandible, while the others were only treated on the upper jaw. Sixty implants were inserted, 22 of which were inserted in fresh extraction sockets.

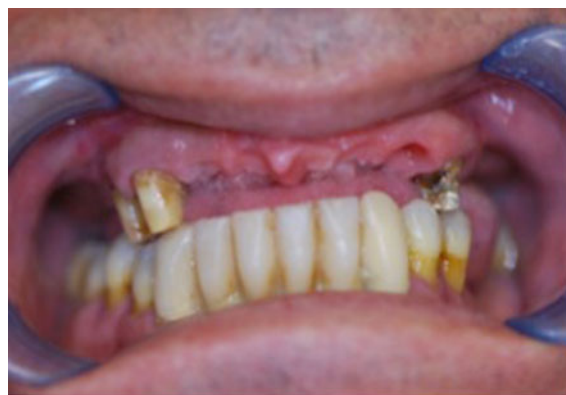For all cases, the following prosthetic and surgical protocol was used. The patients were subjected to a clinical evaluation, and a medical history was taken. Informed consent was collected. Preliminary screenings, including intraoral and panoramic radiographs, (Fig. 1) were performed. Eligible patients received oral hygiene instructions, and impressions and baseline photographs of their dentition were taken. Aesthetic and functional evaluations were done and a facial bow was used to register upper maxilla position. In the laboratory, cast models were mounted in a semi adjustable articulator and it was confirmed that all patients needed implant supported cross-arch prosthesis restoration.

After the diagnostic phase it was determined that for all patients, the teeth would be removed and the implants inserted with a computer-assisted protocol that performed tooth extraction and immediate loading simultaneously.

From each impression, a wax setup was developed and a dental-supported provisional prosthesis was customized



**Fig. 1** Pre operative OPG of hopeless teeth

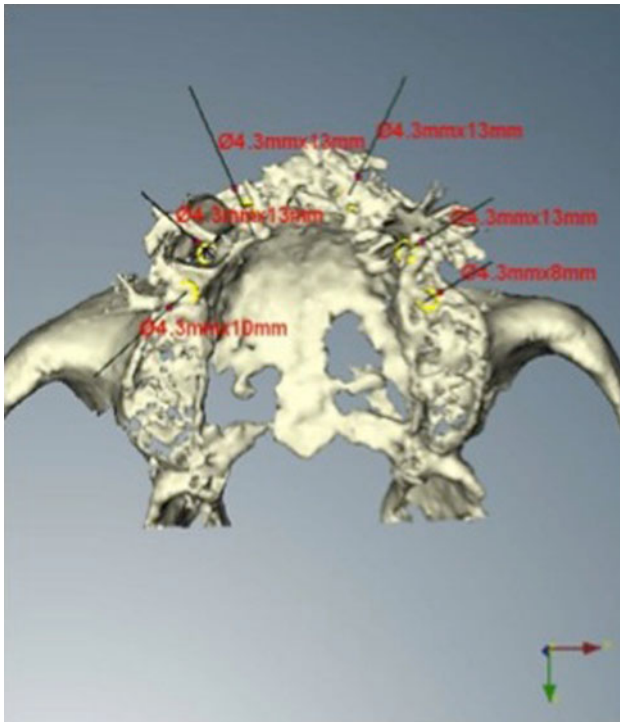


**Fig. 2** Hopeless teeth, left to support for a few months a provisional prosthesis

according to the aesthetic and functional evaluations. Only three or four long-term hopeless teeth were left in the oral cavity of each patient to support, for few months the provisional prosthesis while the other teeth were immediately extracted (Fig. 2). In all cases, we waited for a minimum of 2 to a maximum of 4 months for alveolar bone healing and a radiological template was made according to the aesthetic and functional wax-setup. A silicone interocclusal record was also made as a radiographic index.

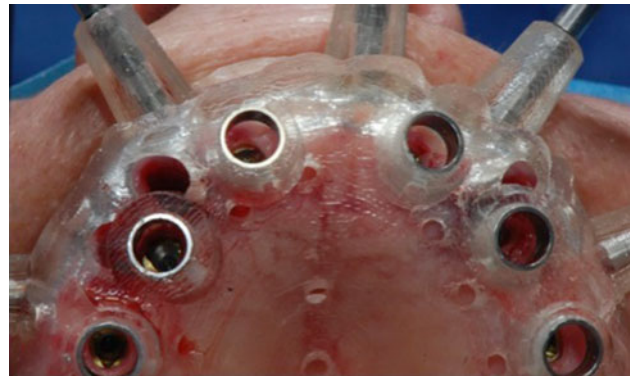
In accordance with the NobelGuide™ data acquisition protocol (Nobel Biocare, Gothenburg, Sweden), two CT scans were performed: one of the patient wearing the radiographic guide as well as the radiographic index, and the other of the template alone. CT scan data were transferred to the NobelGuide Procera® software program for 3D diagnostic analysis and virtual implant planning (Fig. 3). Anatomical conditions had to allow the placement of at least six implants in the ideal position for prosthetic rehabilitation. When an implant was planned with the software, it was very easy to see the tooth to extract, as well as the vestibular and palatal cortical bones. After bone volume analysis, implants were planned on a palatal or lingual site and the implant platform position was programmed 2 mm below the coronal part of the vestibular alveolar crest. The software planning data were sent to the manufacturer (Nobel Biocare, Gothenburg, Sweden), where a surgical template with hollow metallic sleeves was produced to guide the implants according to the positions identified with the planning software. Based on the surgical guide and the model obtained from Nobel Biocare, full acrylic resin screw-retained provisional prostheses were prefabricated.

The surgical procedure was performed under local anaesthesia with articaine chlorhydrate plus 1:100,000 adrenaline (Pierrel S.p.A, Milan Italy). All patients were given diazepam (Valium, 10 mg, Roche US) as a sedative

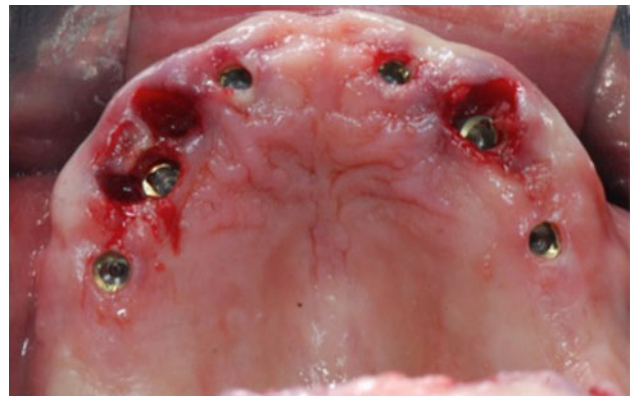


**Fig. 3** Virtual implant insertion, planned in extraction socket

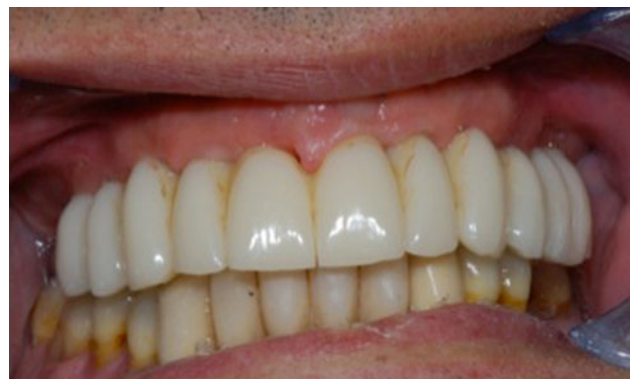agent before surgery. Antibiotics (amoxicillin 875 mg and clavulanic acid 125 mg GlaxoSmithKline S.p.A., Verona, Italy) were given 1 h before surgery and twice a day for 6 days thereafter. An anti-inflammatory drug (ketoprofen 80 mg Dompe' S.p.A, Milan, Italy) was administered twice a day for 4 days post-operatively. An antacid agent (omeprazole 20 mg, Pensa Pharma S.p.A, Milan Italy) was given on the day of surgery and once daily for 6 days post-operatively. Each patient rinsed with chlorhexidine gluconate (0.2 %) for 1 min before the intervention (Curasept, Curaden Healthcare srl, Saronno, Varese, Italy). Surgical templates were placed intraorally in the right position and in relation to the opposing arch and then fixed with three or more anchor pins. Considerable care was taken when placing the surgical template due to the presence of the teeth. After correct placement and stabilisation of the surgical template, flapless implant surgery was performed in accordance with the drilling protocol for the type of implant used (NobelReplace Tapered Groovy, Nobel Biocare, Gothenburg, Sweden) (Figs. 4, 5). Implants were inserted with a pre-set insertion torque of 35–45 Ncm. The implant length ranged from 8 to 13 mm and the implant diameter was 4.3 or 5 mm. In all fixtures installed in fresh extraction sockets, the space between the vestibular cortex and the implant surface was filled with bovine bone grafts (BiOSS Geistlich, Wolhusen, Swiss), and collagen or connective tissue was used to cover the graft and thicken the soft tissues.



**Fig. 4** Surgical template in oral cavity



**Fig. 5** Implant inserted in edentulous jaw and two extraction sockets



**Fig. 6** Immediate loading with screw retained provisional prosthesis

All implants were immediately loaded with the prefabricated screw-retained provisional prosthesis (Fig. 6). When needed, minor adjustments were made to correct occlusion. In all post-extraction sites, the profile of the prosthesis was recontoured with resin to provide better support for the soft tissues. Ice packs were provided and a soft diet was recommended for 1 month. All patients were included in an implant maintenance program. Smokers



were asked to refrain from smoking for at least 48 h post-operatively. Chlorhexidine gluconate mouthwash (0.2 %) was prescribed, for 1 min, twice a day for 2 weeks. The patients were instructed on oral hygiene, and they returned every 3 months for a maintenance appointment. To be deemed successful, implants were required to meet all of the following criteria: clinical stability, patient-reported functionality without any discomfort, and the absence of infection. After 6 months, the prostheses were removed and the implants were individually tested for stability. The definitive prosthetic restorations, either Procera Implant Bridge Titanium as the framework with composite resin as aesthetic material or Procera Implant Bridge Zirconia (Nobel Biocare, Gothenburg, Sweden) with ceramic, were then used.

Outcome measures were radiographic marginal bone-level changes, survival of implants, and patient satisfaction. Peri-implant marginal bone levels were evaluated on intraoral radiographs taken with the parallel technique at the time of implant placement and at 6 months and 1 year after. If radiographs were inconclusive, they were repeated. A radiologist unaffiliated with the study centre interpreted all radiographs. The distances from the mesial and distal interproximal bone to the reference point (the horizontal interface between the implant and abutment) were measured to the nearest 0.1 mm, and the mean of these two measurements was calculated for each implant. The measurements were recorded with reference to the implant axis. Implants were considered successful after 12 months if no pain or mobility was caused under unscrewing torque of 30 Ncm.

## Results

The follow-up period was of at least 12 months. All of the patients felt comfortable and none withdrew from the study. No implants were lost, resulting in a cumulative survival rate of 100 %. Implant survival was tested according to the following criteria:

- It fulfilled its purported function as support for reconstruction,
- It was stable when individually and manually tested,
- No signs of infection observed,
- No radiolucent areas around the implants,
- Allowed a construction of the implant-supported fixed prosthesis, which provided patient comfort and good hygiene maintenance.

Every patient rated the corrective prosthetic rehabilitation with a high degree of satisfaction when it came to masticatory function, social function, and overall quality of life. Radiological estimation showed a mean peri-implant

**Table 1** Peri-implant marginal bone levels after 6, 12 months of follow-up

Months	6	12
No implants	60	60
Mean	1.20	1.40
SD	0.20	0.30

marginal bone loss of  $1.4 \pm 0.3$  mm (Table 1). No other complications, biological or mechanical, were recorded. Soft tissues were healthy with no signs of inflammation. Fixtures inserted in fresh extraction sockets appeared to be in healthy condition and no dehiscence or fixture exposition was recorded in post-extractive sites. In all cases, patients appeared to be very satisfied with the aesthetic and function.

## Discussion

A good number of clinical studies have indicated that immediate loading of oral implants yield acceptable to excellent results in full-arch prosthetic restorations. Some [8, 9] have reported high survival rates in both the maxilla (between 93 and 99.2 % with 15 years of follow-up) and mandible (between 93.2 and 100 % with 15 years of follow-up).

A growing number of retrospective studies have also reported a high success rate for patients restored using the All-on-four and All-on-six treatment protocols combined with computer-guided flapless implant surgery [3]. The advantages of computer-assisted protocols include the minimally invasive approach (flapless surgery or only a small access incision to preserve keratinized gingiva), which improves implant insertion by allowing it to be mapped and planning virtually before the actual surgery. It also allows clinicians to order a surgical template that helps guide the implants during the surgery, and makes it possible to fabricate a screw-retained provisional prosthesis before implant insertion.

The literature concerning implants inserted into fresh extraction sockets is mixed. Some studies affirm that implants cannot preserve the alveolar bone and that immediate implant insertion in dental sockets is an unpredictable treatment with many aesthetic problems due to unavoidable vestibular cortex resorption [10, 11]. Other authors have reported a high implant success rate when fixtures are inserted immediately after teeth extraction [6–13]. Cantoni and Polizzi [7] developed a new, immediate post-extraction computer-assisted protocol using Procera software and a double radiological template; it seems to be useful but requires further clinical assessment.

We believe that clinicians should comply with patients' requests, and for this reason, we agree with some authors about the need to use minimally invasive techniques and to avoid when possible aesthetic or functional problems associated with the use of removable prosthesis after teeth extractions.

The literature concerning immediate implant insertion into dental sockets is conflicting due to the various implant insertion protocols. For example, Araujo et al. [10] analysed implant insertion with an open flap technique using large implants and without grafting the space between the fixture and vestibular alveolar bone. This approach is likely to be accompanied by extensive vertical and width bone resorption caused by implant trauma and the unavoidable vestibular resorption caused by full-thickness flaps.

Therefore, complete teeth removal and immediate implant insertion into fresh sockets could have a high implant success rate, but could also cause many aesthetic and prosthetic problems, especially on the upper jaw, due to the vestibular bone resorption and the inherent difficulty in performing a correct wax-up when many damaged teeth are still present in the patient's mouth.

For this reason, we developed a new prosthetic and surgical protocol that is easy to apply, does not require a long learning curve, involves only a few implants that are inserted into dental sockets, and only uses a single radiological template.

Obviously some limitations exist. For one, severely damaged teeth may not be able to support a provisional prosthesis for a few months. In such cases, it may be preferable to use a removable prosthesis and to wait for complete bone remodelling before implant installation.

In conclusion, we believe that immediate implant insertion into fresh dental sockets represents a valid opportunity for clinicians, especially when a full-arch implant-supported restoration is needed, but some parameters have to be considered if the goal is not only implant insertion, but also prosthetic and aesthetic results. Within the limitations of this study (number of patients and implants inserted), our data seem to validate this surgical and prosthetic protocol with valid functional and aesthetic results.

**Acknowledgments** We acknowledge Andrea Cialente for his technical support.

**Conflicts of interest** None of the authors have direct financial relation with the commercial identity mentioned in the text.

## References

- Johansson B, Friberg B, Nilson H (2009) Digitally planned, immediately loaded dental implants with prefabricated prostheses in the reconstruction of edentulous maxillae: a 1-year prospective, multicenter study. *Clin Implant Dent Relat Res* 11:194–200
- Maló P, Rangert B, Nobre M (2005) All-on-4 immediate-function concept with Brånemark System implants for completely edentulous maxillae: a 1-year retrospective clinical study. *Clin Implant Dent Relat Res* 7(Suppl 1):S88–S94
- Meloni SM, De Riu G, Pisano M, Cattina G, Tullio A (2010) Implant treatment software planning, guided flapless surgery with immediate provisional prosthesis delivery in the fully edentulous maxilla. A retrospective analysis of 15 consecutively treated patients. *Eur J Oral Implantol* 3:245–251
- Bedrossian E (2007) Laboratory and prosthetic considerations in computer-guided surgery and immediate loading. *J Oral Maxillofac Surg* 65(7 Suppl 1):47–52
- Van Steenberghe D, Naert I, Andersson M, Brajnovic I, Van Cleynen-breugel J, Suetens P (2002) A custom template and definitive prosthesis allowing immediate implant loading in the maxilla: a clinical report. *Int J Oral Maxillofac Implants* 17:663–670
- Villa R, Rangert B (2007) Immediate and early function of implants placed in extraction sockets of maxillary infected teeth: a pilot study. *J Prosthet Dent* 97(6 Suppl):S96–S108
- Cantoni T, Polizzi G (2009) Implant treatment planning in fresh extraction sockets: use of a novel radiographic guide and CAD/CAM technology. *Quintessence Int* 40:773–781
- Engquist B, Astrand P, Anzen B, Dahlgren S, Engquist E, Feldmann H, Dahlgren S, Engquist E, Feldmann H, Karlsson U, Nord PG, Sahlholm S, Svärdröm P (2006) Simplified methods of implant treatment in the edentulous lower jaw: a 3-year follow-up report of a controlled prospective study of one-stage versus two-stage surgery and early loading. *Clin Implant Dent Relat Res* 7:95–104
- Fortin Y, Sullivan RM, Rangert BR (2002) The Marius implant bridge: surgical and prosthetic rehabilitation for the completely edentulous upper jaw with moderate to severe resorption: a 5-year retrospective clinical study. *Clin Implant Dent Relat Res* 4:69–77
- Araújo MG, Sukekava F, Wennström JL, Lindhe J (2006) Tissue modeling following implant placement in fresh extraction sockets. *Clin Oral Implants Res* 17:615–624
- Araújo MG, Wennström JL, Lindhe J (2006) Modeling of the buccal and lingual bone walls of fresh extraction sites following implant installation. *Clin Oral Implants Res* 17:606–614
- Villa R, Crespi R, Capparè P, Gherlone E (2010) Immediate loading of a dental implant placed in fresh socket with acute dehiscence-type defect: a clinical case report. *J Periodontol* 81:953–957
- Polizzi G, Grunder U, Goené R, Hatano N, Henry P, Jackson WJ, Kawamura K, Renouard F, Rosenberg R, Triplett G, Werbit M, Lithner B (2000) Immediate and delayed implant placement into extraction sockets: a 5-year report. *Clin Implant Dent Relat Res* 2:93–99