

Horizontal Ridge Augmentation using GBR with a Native Collagen Membrane and 1:1 Ratio of Particulated Xenograft and Autologous Bone: A 1-Year Prospective Clinical Study

Meloni Silvio Mario, DDS, PhD, MSc;* Jovanovic Sascha A, DDS, MS;† Urban Istvan, DDS, MD, MS;‡
Canullo Luigi, DDS, PhD;§ Pisano Milena, DDS;# Tallarico Marco, DDS, MSc^{||}

ABSTRACT

Aim: To clinically and radiographically evaluate bone regeneration of severe horizontal bone defects.

Materials and Methods: This study was designed as a single cohort, prospective clinical trial. Partially or fully edentulous patients, having less than 4 mm of residual horizontal bone width were selected and consecutively treated with resorbable collagen membranes and a 1:1 mixture of particulated anorganic bovine bone and autogenous bone, 7 months before implant placement. Tapered body implants were inserted and loaded 3 to 6 months later with a screw retained crown or bridge. Outcomes were: implant survival rate, any biological and prosthetic complications, horizontal alveolar bone dimensional changes measured on cone beam computed tomography (CBCT) taken at baseline and at implant insertion, peri-implant marginal bone level changes measured on periapical radiographs, plaque index (PI), and bleeding on probing index (BoP).

Results: Eighteen consecutive patients (11 females, 7 males) with a mean age of 56.8 years (range 24–78) and 22 treated sites received 55 regular platform implants. No patient dropped-out and no implants failed during the entire follow-up, resulting in a cumulative implant survival rate of 100%. No prosthetic or biological complications were recorded. Supraimposition of pre- and 7-month post-operative CBCT scans revealed an average horizontal bone gain of 5.03 ± 2.15 mm (95% CI: 4.13–5.92 mm). One year after final prosthesis delivery, mean marginal bone loss was 1.03 ± 0.21 mm (95% CI 0.83–1.17 mm). PI was 11.1% and BoP was 5.6%.

Conclusion: Within the limitation of the present study, high implant survival rate and high average bone augmentation seem to validate the use of collagen resorbable membranes with a 1:1 mixture of particulated anorganic bovine bone and autogenous bone, for the reconstruction of severe horizontal ridge defects.

KEY WORDS: alveolar ridge reconstruction, atrophy, autologous bone, bone augmentation, bone defects, bone regeneration, bone substitutes, xenograft

Conflict of Interest Statement: This Study was not supported by any company and all the authors have not conflict of interest.

*Assistant Professor, University of Sassari, Italy; †associated professor, Loma Linda University, CA, USA; ‡Assistant professor, Loma Linda University, CA, USA; Urban Regeneration Institute, Budapest, Hungary; §Independent Researcher in Rome, Rome, Italy; #private practice in Sassari, Italy; ||Lecturer, University of Sassari, Italy

Corresponding Author: Dr. Marco Tallarico, Via di Val Tellina 116, Rome, Italy; e-mail: me@studiomarcotallarico.it

© 2016 Wiley Periodicals, Inc.

DOI 10.1111/cid.12429

INTRODUCTION

Dental implant has become a predictable treatment option, with excellent long-term results.¹ However, the success of implant therapy depends on the amount of bone volume at the insertion site.² Unfavorable local conditions may provide insufficient bone volume that negatively affects the prognosis of dental implants.^{3,4} Cawood and Howell in 1988 ranked the atrophy degree of edentulous jaws in six classes.⁵ Particularly, atrophies within class IV, also known as “knife-edge” ridges, present a serious horizontal defect, making challenging the placement of regular implants.

Many techniques have been developed to regenerate atrophic alveolar jaws for the placement of dental implants, performed either in combination with graft procedures or in second stage surgery after a period of healing.⁶ For many years, bone blocks represented the gold standard to reconstruct the alveolar ridge bone defects. This technique requires to harvest a wide amount of bone to rebuild the atrophic crest.⁷ For this reason, bone blocks were often harvested from extra-oral sites with an higher morbidity.⁴ Moreover some problems can occur when a combined defects (horizontal and vertical) need to be treated. Guided bone regeneration (GBR) has been proposed as a possible alternative for patients with severe horizontal bone atrophy, to overcome the drawback of bone blocks techniques.^{6,8} To protect and prevent the invasion of the clot by non-osteogenic cells, maintaining an adequate biological space for the regeneration of bone tissue, the use of both non-resorbable or resorbable membranes,⁹ in combination with autologous or heterologous particulate bone have been proposed.¹⁰ Expanded polytetrafluoroethylene (e-PTFE) membranes are the most used non-resorbable membranes with the longest published follow-up, considering them the gold standard in the reconstructions of major horizontal bone defects. However, a second surgery is needed to remove them and they may get exposed in the oral cavity and contaminate with possible infection and graft loss.¹¹ Conversely, the resorbable membranes most advantages are an ability to merge with the host tissues, as well as a rapid resorption in case of exposure, thereby reducing the risk of bacterial contamination.¹² Resorbable membranes in combination with particulated anorganic bovine bone (ABB) can be used for the augmentation of horizontally deficient ridges.¹³ Particulated autogenous bone can be mixed with bone substitutes to add more osteogenic factors.^{14,15}

The aim of this prospective study is to evaluate clinical and radiographic data of patients treated with resorbable collagen membranes, a mixture of ABB and autogenous particulated bone in 1:1 ratio, and waiting 7 months before implant placement, for the reconstruction of severe horizontal bone defects (<4mm). This report was written in accordance with the STROBE (STrengthening the Reporting of OBservational studies in Epidemiology) guidelines.

MATERIALS AND METHODS

This study was design as single cohort prospective observational study aimed to evaluate patients with severely resorbed posterior mandible or maxilla. Private patients were selected and treated in one private centre in Sardinia (Italy), from June 2013 to April 2014. Data were analyzed at the Surgical, Micro-surgical and Medical Science department of the University of Sassari, Italy. One experienced clinician performed all surgical procedures (SMM). Another clinician (MP) delivered all the prosthetic restorations. The investigation was conducted according to the principles embodied in the Helsinki Declaration of 1964 for biomedical research involving human subjects, as amended in 2008. No Ethical Committee approval was request. All patients were duly informed about the nature of the study and gave their written consent.

Inclusion criteria were: any patients aged 18 years or older, who presented with posterior partial or total edentulism of the mandible or maxilla, with residual horizontal ridge thickness of 4 mm or less (Cawood-Howell Class IV,³ who required an implant supported restoration, and able to understand and sign an informed consent form was eligible for inclusion in this study.

Patients were not admitted in the study if any of the following exclusion criteria was present:

1. American Society of Anesthesiologist (ASA) class III or IV;
2. Psychiatric contraindications;
3. Pregnancy or nursing;
4. Alcohol or drug abuse;
5. Heavy smoking (>10 cigarettes/day);
6. Radiation therapy to head or neck region within 5 years;
7. High and moderate parafunctional activity;
8. Absence of teeth/denture in the opposite jaw;
9. Untreated periodontitis;
10. Immediate post-extractive implants;
11. Full mouth bleeding and full mouth plaque index higher than or equal to 25%;
12. Unavailability for regular follow-ups.

Surgical and Prosthetic Protocol

Medical history of the patients was collected and study models were made. Preoperative photographs

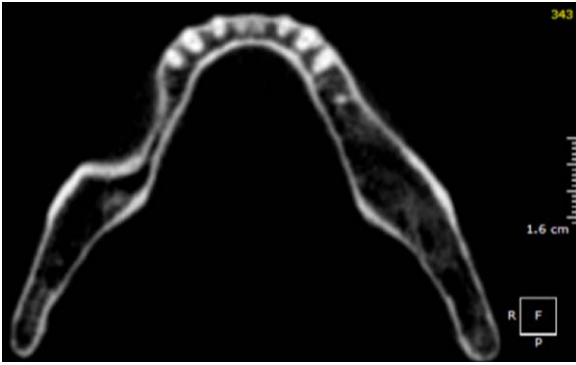


Figure 1 CBCT Scan before horizontal augmentation.

and radiographs including cone beam (CBCT, CRANEX 3D; Soredex, Tuusula, Finland) were obtained for initial screening and evaluation (Figure 1). Smokers patients were advised to refrain from smoking four weeks before and four weeks after surgery. Patients received amoxicillin 2 g (Zimox, Pfizer, Rome, Italy) 1 hour before surgery and then 1 g twice daily for 1 week. In the event of a penicillin allergy, clindamycin (600 mg) was administered for premedication and following surgery (300 mg 4 times a day for 1 week). Patients were instructed to rinse with 0.2% chlorhexidine solution (Curasept, Curaden Healthcare S.p.A., Saronno, Varese, Italy) for 1 minute to disinfect the surgical site and a sterile surgical drape was applied to minimize the potential contamination from extraoral sources. Oral sedation with triazolam 0.50 mg (Triazolam ratiopharm Italia), was given prior to surgery. Local anaesthetic (Septanest with adrenaline, 1/100,000, Septodont) was used.

A midcrestal incision into the keratinized tissue was made using a surgical blade, and a full-thickness flap was elevated beyond the mucogingival junction and at least 5 mm beyond the bone defect. Two vertical incisions were placed at least one tooth away from the area to be augmented, while, in edentulous areas, vertical incisions were placed at least 5 mm away from the planned surgical site. In the posterior mandible, a lingual flap was elevated beyond the mylohyoid line, and sensitive anatomical structures (e.g., mental and infraorbital nerves) were protected. Before bone collection, the recipient site was cleaned by removing all soft tissue remnants. Autogenous bone was harvested from the retromolar regions using a minimally invasive cortical bone collector (Micros, Meta, Italy). In case of maxillary sites, an

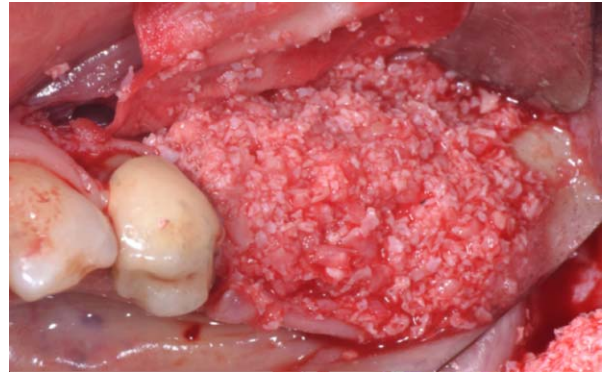


Figure 2 Mixed 1:1 particulated anorganic bovine bone and autologous bone.

additional flap was elevated for the bone harvesting procedure. Multiple decortication holes at the recipient site was performed with a 2.0 mm round bur. A collagen membrane (Bio-gide, Geistlich Biomaterials Italia S.r.l., Italy) was fixed with five titanium pins (Supertack, MCbio s.r.l., Lomazzo, Italy), three on the buccal and two on the lingual/palatal side. The third tack in mid buccal side was used to prevent apical movement of the bone graft. The autogenous bone grafted material was mixed with anorganic bovine bone material (Bio-OSS, Geistlich Biomaterials Italia S.r.l.) in a 1:1 ratio, and it was placed into the buccal and lingual/palatal side of the defect (Figure 2). The membrane was trimmed to the entire volume of the graft. Additional titanium pins were placed on the vestibular side (Figure 3). Maxillary cases were combined with a sinus augmentation procedure, when indicated, to achieve additional apical bone height for subsequent implant placement. No other combination grafting procedures were performed. A periosteal incision between the two vertical incisions was performed to allow a completely tension-free closure of the flap. In the mandible, both the lingual and the buccal flaps were released. The flaps were then sutured in two layers in order to prevent exposure of the membrane. Horizontal mattress sutures (4-0 Vycril, Ethicon, Johnson & Johnson, Italy) were first placed 4 mm from the incision line; then, single interrupted sutures were placed to close the edges of the flap. Vertical incisions were sutured with single interrupting sutures (4-0 Vycril, Ethicon, Johnson & Johnson, Italy). The single interrupted sutures were removed between 10 and 14 days post-surgery, and mattress sutures were removed 2 to 3 weeks after surgery.

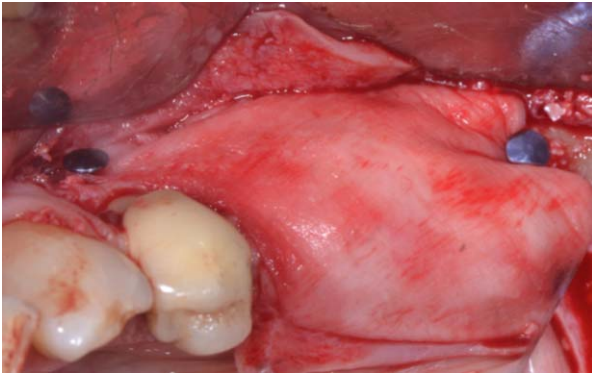


Figure 3 Horizontal GBR with collagen membrane.

Postoperatively, 5 mg of Oxycodone Hydrochloride (Mundipharma Pharmaceuticals, Milan, Italy) two times daily was prescribed for the first day and then as needed. Betamethasone (Biofutura Pharma, S.P.A., Pomezia, roma, Italy) 4 mg was administered immediately after surgery. Patients were instructed to continue antibiotic therapy as prescribed and to rinse with 0.2% chlorhexidine (Curasept, Curaden Healthcare S.p.A., Saronno, Varese, Italy) for 2 weeks and to follow a soft food diet for 10 days.

Seven months after ridge reconstruction, CBCT scan was obtained to assess graft material integration and to measure the horizontal crest augmentation (Figure 4). Implants were placed submerged, according to the manufacturer with an insertion torque ranging between 30 Ncm and 45 Ncm, as measured with the manual torque wrench by the surgeon. Three to 6 months after implant placement a screw retained zirconia ceramic final crowns were delivered. All patients were followed for at least 12 months after loading (Figures 5 and 6). Hygiene maintenance and occlusal control were planned every 6 months after loading.

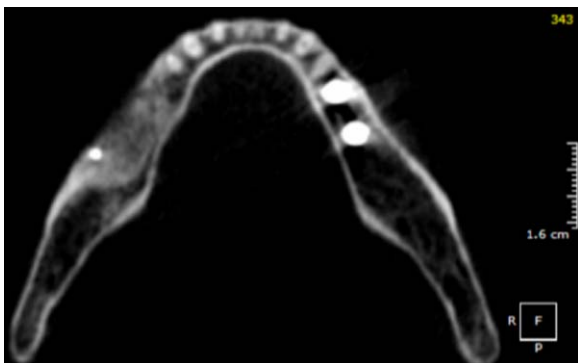


Figure 4 CBCT Scan after horizontal augmentation.

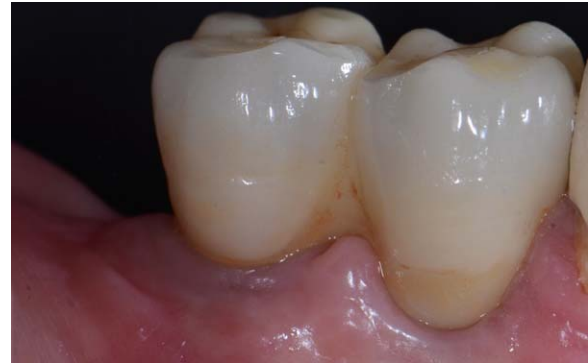

Figure 5 One-year after loading follow-up.

Primary Outcome Measures Were.

1. Implant and prosthetic survival rates, and any biologic (pain, swelling, mobility, membrane exposure, suppuration) and/or technical complications (framework and/or veneering material fracture, screw loosening).
2. Any complications during bone graft healing, such as membrane exposure, subsequent infection, and/or morbidity associated with the harvest site, were recorded. Periapical radiographs were obtained at the time of abutment connection and every 12 months thereafter with a long-cone paralleling technique. Functionally loaded implants were monitored to evaluate the following: absence of pain, foreign-body sensation, and/or dysesthesia; and radiologic contact between the host bone and the implant surface.

Secondary Outcome Measures were. 1. Horizontal and volumetric dimensional changes. CBCT scans were performed before ridge reconstruction and 7 months after. The Digital Imaging and Communication in Medicine (DICOM) data were exported the

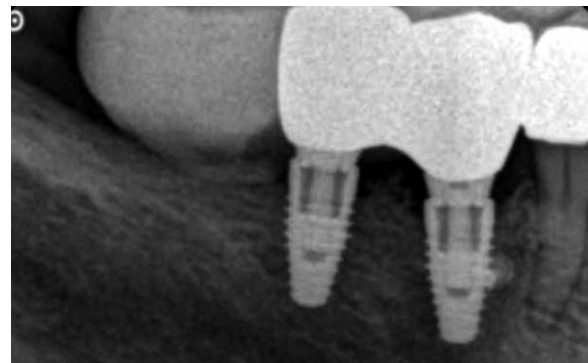


Figure 6 Periapical radiograph taken 1-year after loading.

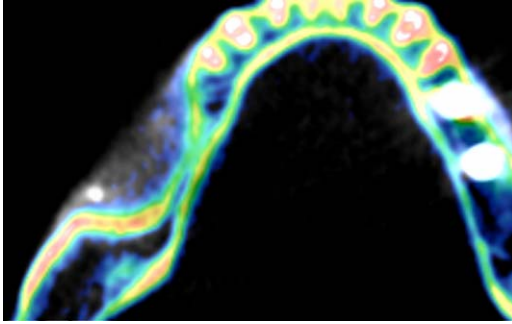


Figure 7 Superimposition of baseline and 7 months CBCT scan.

OnDemand 3D software version 1.0.9.3223 (Cybermed Inc., Seoul, Korea) to perform all measurements. Superimposition of the DICOM data were automatically performed according to a voxel-based registration method.^{16–18} The DICOM data were manually aligned based on unchanged anatomical areas (e.g., teeth, basal skull, implants) and then automatically matched using the Fusion adjunctive module (Cybermed Inc. Seoul, Korea). Horizontal bone measure was recorded for all reconstructed ridge 2 mm below the bone crest, before and after treatment. Then, the postoperative volumetric data were subtracted to the original scenario. The new generated set of DICOM data were stored as a separately files. Volumetric measurements of grafts were performed with OnDemand 3D software (Cybermed Inc., Seoul, Korea) using the previously generated set of DICOM data (Figure 7). The volumes of the grafted material were calculated using automatic tools, basing on its opacity.

2. Peri-implant marginal bone level: mesial and distal bone level changes were measured as the distance from the most coronal margin of the implant collar and the most coronal point of the bone-to-implant contact, evaluated on intraoral digital radiographs taken with the paralleling technique using a film-holder (Rinn XCP, Dentsply, Elgin, IL, USA). Radiographs were taken at implant placement (baseline), at implant loading, and after one-year on function. The radiographs were accepted or rejected for evaluation based on the clarity of the implant threads. All readable radiographs were displayed in an image analysis program (Digora for Windows version 2.8, Soredex) on a 24-inch LCD screen (iMac, Apple, Cupertino, CA, USA) and evaluated under standardized conditions (SO 12646:2004). The software has

TABLE 1 Baseline Characteristics of Selected Patients

| | |
|-------------------------------------|--------------------|
| Mean age (range) | 56.8 years (24–78) |
| Female/male ($n = 18$) | 11/7 |
| Smokers (≤ 10 cigarettes/day) | 8 |
| Single cases | 3 |
| Partial cases | 14 |
| Fully edentulous cases | 1 |
| Maxillary/Mandibular cases | 10/8 |

been calibrated for every single image using the known distance of two adjacent threads. Measurements of the mesial and distal bone crest level adjacent to each implant were made to the nearest 0.01 mm and averaged at patient level. Peri-implant marginal bone loss was calculated as the difference between timepoints.

3. Plaque index (PI), defined as plaque absent or present (0/1), and Bleeding on Probing (BoP), defined as bleeding on probing absent or present (0/1), were recorded one year after final prosthesis delivery.

One assessor, (AD) not previously involved in the study, made all the clinical outcomes. Volumetric dimensional changes, as well as the peri-implant marginal bone level changes were evaluated by an expert radiologist not previously involved in the study (GF). Complications were evaluated and treated by the same clinician that performed the surgical procedures.

Statistical Analysis

All data analysis was carried out according to a pre-established analysis plan. Patient data were compiled from the records of the eligible patients using an Excel spreadsheet (Microsoft) that reflected the parameters in the patient records. The data were then exported into SPSS software for Mac OS X (version 22.0; SPSS Inc., Chicago, IL, USA) for the statistical analysis. A bio-statistician with expertise in dentistry analyzed the data using SPSS for Windows release 18.0 (SPSS, Chicago, IL, USA), without knowing the group codes. Descriptive analysis was performed for numeric parameters using means \pm standard deviations (95% confidence interval, CI). Comparisons between each time point and the baseline measurements were made by paired tests, to detect any changes in volumetric dimensional of the ridge.

TABLE 2 Horizontal Bone Width

| | Baseline (mm) (Mean \pm SD, 95% CI) | 7 months (Mean \pm SD, 95% CI) | Difference (Mean \pm SD, 95% CI) | <i>p</i> -value |
|-----------------------|--|-------------------------------------|---------------------------------------|-----------------|
| Horizontal bone level | 3.07 \pm 0.64 (2.8 – 3.34) | 8.09 \pm 2.16 (7.19 – 8.99) | 5.03 \pm 2.15 (4.13 – 5.92) | .000* |

Differences in the proportion of patients with early collagen membrane exposure and smoking were compared using the Fisher's exact probability test. The patient was the statistical unit of the analyses. All statistical comparisons were conducted at the 0.05 level of significance.

RESULTS

Twenty patients were screened for eligibility but two patients were not enrolled in the trial, because of the refusal to undergo a CBCT scan. Eighteen consecutive patients (7 males 11 females) with a mean age of 56.8 years (range 24–78) with 22 surgical sites classified as Cawood-Howell Class IV¹⁵ received at least one GBR procedure each, followed by placement of 55 regular platform 4.3 mm implants. (NobelReplace Conical Connection, PMC, Nobel Biocare) 6 maxillary procedures were associated with sinus lift elevation. Eight out of 18 patients (44.4%) were light smokers. However, 4 patients stopped smoking before surgery, and they have not restarted. The main patients and interventions characteristics are summarized in Table 1.

At the 1-year follow-up examination, no patient dropped out and no deviation from the original protocol occurred. All the collected data were included in the statistical analysis. No implant failed, resulting in a cumulative implant and prosthetic survival rate of 100%. No prosthetic complication was observed. No major biological complications were recorded. In three patients (13.6%) the collagen membrane was exposed 2 weeks after bone reconstruction. Two of these patients were light smokers, however, the Fisher's exact test failed to find significant association ($p = .559$) between smoking habit and early membrane exposure. In these situations, the area was treated with local application of chlorhexidine gel

0.5% (Curasept ADS 0.5% gel parodontale, Curaden Healthcare S.p.A., Saronno, Varese, Italy) twice per day, for 3 weeks. Complete soft tissue healing was observed in all the three cases.

The mean horizontal alveolar ridge width was 3.07 \pm 0.64 mm (95% CI 2.80 – 3.34 mm). At the 7-month follow-up examination, the mean bone width was 8.09 \pm 2.16 mm (95% CI 7.19–8.99 mm). The mean bone gain was 5.03 \pm 2.15 mm (95% CI 4.13–5.92 mm). The difference was statistically significant ($p = .000$), (Table 2). The mean volume of the grafted bone calculated using the supraimposition technique was 1.12 \pm 0.18 CC (95% CI 1.01–1.23 CC).

One year after loading, the mean peri-implant marginal bone loss was 1.03 \pm 0.21 mm (95% CI 0.83–1.17 mm), (Tables 3 and 4). Plaque index was scored at 11.1% of all implants; while 5.6% of the implants showed positive BoP.

DISCUSSION

The aim of this prospective study was to investigate the 1-year after loading clinical and radiographic data of guided bone regeneration procedure using particulated autologous bone and anorganic bovine bone with ratio 1:1 in combination with a resorbable membrane for horizontal augmentation of knife-edged ridges.

The main limitations of the present study were the low number of treated patients and the relative short follow-up. Nevertheless, even though the number of patients enrolled in this study can not ensure definitive conclusions, a total of 55 implants were placed in 22 augmented sites. Post hoc analysis given a compute achieved power of 100%, allowing the results of the present study to be generalized to a larger population with similar characteristics.

TABLE 3 Marginal Bone Levels (mm) (Mean \pm SD, 95% CI)

| | Implant placement | Implant loading | 12 months after loading |
|----------------------|----------------------------|-----------------------------|----------------------------|
| Marginal bone levels | 0.12 \pm 0.06 (0.04–0.2) | 0.79 \pm 0.36 (0.40–1.20) | 1.16 \pm 0.16 (1.02–1.3) |

TABLE 4 Differences in Marginal Bone Levels (mm) (Mean \pm SD, 95% CI)

| | Implant placement to Implant loading | Implant loading to 12 months after loading | Implant placement to 12 months after loading | <i>p</i> -value |
|-------------|---|---|---|-----------------|
| Differences | 0.76 \pm 0.32 (0.42–1.06) | 0.37 \pm 0.14 (0.24–0.46) | 1.03 \pm 0.21 (0.83–1.17). | .000* |

In the present study, an implant cumulative survival rate of 100% and successful marginal remodeling were experienced, supporting the feasibility of collagen resorbable membrane in GBR procedures for horizontal ridge augmentation. Although the two stages approach needs a longer time before prosthesis delivery, this technique seems to be safe and predictable also for large reconstruction and can be applied in daily practice. A systematic review by Aghaloo and Moy reported a statistically significant reduced implant survival rates at sites grafted with autogenous bone block, compared with other regenerative techniques.² Their meta-analysis found an implant survival rate of 74.4% for iliac crest grafts, as compared with 95.5% for GBR.

In the present study, three patients experienced early collagen membrane exposure. Although 2 out of 3 patients were light smokers, the Fisher's exact test ($p = .559$) revealed no significant difference compared to no smoker patients.

In the present study, the mean horizontal bone increase of 5.03 mm (± 2.15 mm), with 7 sites gaining ≥ 7 mm. The results of the present study are in accordance with others reports in the literature indicate that the standard treatment for knife-edged ridges has changed in recent years. Similarly results were obtained by Urban et al. (5.68 \pm 1.42 mm), in a prospective case series study.¹⁴ Nevertheless, measurements of the alveolar ridge width were taken at the time of grafting and then at implant placement, using a caliper 2 mm apically from the top of the crest.

In the present study, the bone graft healing was uneventful in all patients and a sufficient bone volume for implant installation was obtained also in 3 cases of membrane exposure.

Non resorbable e-PTFE membranes are still considered the gold standard in GBR;¹⁵ however, frequently reported soft tissue problems, as well as the need to remove the membrane, have led to the development and use of resorbable membranes.¹⁴ The lack of titanium reinforcement for the collagen membrane

can be overcome by an accurate fixation of the membrane with titanium pins on both the lingual/palatal and the vestibular side. With a secure fixation the membrane immobilizes the graft material until the complete resorption, allowing the formation of the desired amount of bone.

The use of bone grafting materials and resorbable membranes to treat severe horizontal defects may lead to less morbidity in the treatment of patients with these defects. In addition, the use of 50% ABBM in these procedures reduces the need for harvested autogenous bone and may generally lead to decreased morbidity and therefore increased patient comfort and satisfaction associated with these regenerative procedures. The absence of major complications in any of the harvest sites in this case series supports the potential benefit of ABBM for these types of procedures. However, the positive results obtained in this prospective study need to be confirmed by randomized and controlled clinical trials with long follow-up.

CONCLUSION

Within the limitation of the present study, high implant survival rate and high average bone augmentation seem to validate the use of collagen resorbable membranes with a 1:1 mixture of particulated anorganic bovine bone and autogenous bone, for the reconstruction of severe horizontal ridge defects. Further studies are needed to confirm these results.

REFERENCES

1. Pjetursson BE, Thoma D, Jung RE, Zwahlen M, Zembic A. A systematic review of the survival and complication rates of implant-supported fixed dental prostheses (FDPs) after a mean observation period of at least 5 years. *Clin Oral Implants Res* 2012; 12:22–38.
2. Aghaloo TL, Moy PK. Which hard tissue augmentation techniques are the most successful in furnishing bony support for implant placement. *Int J Oral Maxillofac Implants* 2007; 22:49–70.
3. Esposito M, Grusovin MG, Coulthard P, Worthington HV. The efficacy of various bone augmentation

- procedures for dental implants: a Cochrane systematic review of randomized controlled clinical trials. *Int J Oral Maxillofac Implants* 2006; 21:696–710.
4. Simion M, Jovanovic SA, Tinti C, Benfenati SP. Long-term evaluation of osseointegrated implants inserted at the time or after vertical ridge augmentation. A retrospective study on 123 implants with 1-5 year follow-up. *Clin Oral Implants Res* 2001; 12:35–45.
 5. Cawood JI, Howell RA. A classification of the edentulous jaws. *Int J Oral Maxillofac Implants* 1988; 17:232–236.
 6. Buser D, Ingimarsson S, Dula K, Lussi A, Hirt HP, Belser UC. Long-term stability of osseointegrated implants in augmented bone: a 5-year prospective study in partially edentulous patients. *Int J Periodontics Restorative Dent* 2002; 22:109–117.
 7. Chiapasco M, Casentini P, Zaniboni M, Corsi E. Evaluation of peri-implant bone resorption around Straumann Bone Level implants placed in areas reconstructed with autogenous vertical onlay bone grafts. *Clin Oral Implants Res* 2012; 23:1012–1021.
 8. Urban IA, Jovanovic S, Lozada JL. Vertical ridge augmentation using guided bone regeneration (GBR) in three clinical scenarios prior to implant placement: a retrospective study of 35 patients 12 to 72 months after loading. *Int J Oral Maxillofac Implants* 2009; 24:502–510.
 9. Urban IA, Caplanis N, Lozada JL. Simultaneous vertical guided bone regeneration (GBR) and guided tissue regeneration (GTR) in the posterior maxilla using recombinant human platelet-derived growth factor (rhPDGF). A case report. *J Oral Implantol* 2009; 35:251–256.
 10. Esposito M, Grusovin M, Worthington H, Coulthard P. Interventions for replacing missing teeth: bone augmentation techniques for dental implant treatment. *Cochrane Database Syst Rev* 2006:CD003607.
 11. Chiapasco M, Abati S, Romeo E, Vogel G. Clinical outcome of autogenous bone blocks or guided bone regeneration with e-PTFE membranes for the reconstruction of narrow edentulous ridges. *Clin Oral Implants Res* 1999; 10:278–288.
 12. Schenk RK, Buser D, Hardwick WR, Dahlin C. Healing pattern of bone regeneration in membrane-protected defects: a histologic study in the canine mandible. *Int J Oral Maxillofac Implants* 1994; 9:13–29.
 13. Buser D, Dula K, Hirt HP, Schenk RK. Lateral ridge augmentation using autografts and barrier membranes: a clinical study with 40 partially edentulous patients. *J Oral Maxillofac Surg* 1996; 54:420–432.
 14. Urban IA, Nagursky H, Lozada JL, Nagy K. Horizontal ridge augmentation with a collagen membrane and a combination of particulated autogenous bone and anorganic bovine bone-derived mineral: a prospective case series in 25 patients. *Int J Periodontics Restorative Dent* 2013; 33:299–307.
 15. Jovanovic SA, Spiekermann H, Richter EJ. Bone regeneration around titanium dental implants in dehiscence sites: a clinical study. *Int J Oral Maxillofac Implants* 1992; 7:233–245.
 16. Maes F, Collignon A, Vandermeulen D, Marchal G, Suetens P. Multimodality image registration by maximization of mutual information. *IEEE Trans Med Imaging* 1997; 16:187–198.
 17. Kim ES, Moon SY, Kim SG, Park HC, Oh JS. Three-dimensional volumetric analysis after sinus grafts. *Implant Dent* 2013; 22:170–174.
 18. Meloni SM, Tallarico M, Lolli FM, Deledda A, Pisano M, Jovanovic SA. Postextraction socket preservation using epithelial connective tissue graft vs porcine collagen matrix. 1-year results of a randomised controlled trial. *Eur J Oral Implantol* 2015; 8:39–48.